

Masterclass

Achilles tendinopathy

J. L. Cook,* K. M. Khan,† C. Purdam‡

*Musculoskeletal Research Centre, La Trobe University, Victoria, Australia; †Department of Family Practice (Allan McGavin Sports Medicine Centre), School of Human Kinetics, University of British Columbia, Canada;

‡Head of Physiotherapy and Massage, Australian Institute of Sport, Canberra, Australia

SUMMARY. Achilles tendon injury (tendinopathy) and pain occur in active individuals, when the tendon is subject to high or unusual load. Achilles tendinopathy can be resistant to treatment, and symptoms may persist despite both conservative and surgical intervention. The pathology of overuse tendinopathy is non-inflammatory, with a degenerative or failed healing tendon response. The diagnosis of Achilles tendinopathy requires excellent differential diagnosis and an understanding of the role of tendon imaging. Conservative treatment must include exercise, with a bias to eccentric contractions. Surgical treatment is effective after complete tendon rupture, but may not assist recovery from overuse tendinopathy. Further research into the clinical aspects of Achilles tendinopathy is required. © 2002 Elsevier Science Ltd. All rights reserved.

INTRODUCTION

Achilles tendon injury is a common sequel to sporting participation. Similar to other tendons, pain classically appears with an increase in training load, or, in elite athletes, sustained high training loads. It appears more prevalent in sports that have a large running component, but occurs in all sports and at all levels of participation. Occasionally, Achilles tendon pain is found in inactive individuals.

Active older individuals may also present with Achilles tendon problems, often with symptoms for the first time. Occasionally, they can recall a previous episode or previous symptoms, or report asymptomatic tendon swelling for an extended period. Although age increases tendon crosslinks and decreases tendon water content (Tuite et al. 1997) and it

may increase the degree of histopathological changes (Astrom & Rausing 1995), aging is not specifically associated with tendinopathy (Maffulli et al. 2000). Adolescent injury is uncommon, and childhood symptoms appear restricted to the region of the growth plate (Cameron et al. 1994).

Injury is most commonly due to overuse, although acute complete ruptures also occur. Partial ruptures, although frequently diagnosed, may represent acute pain from preexisting but asymptomatic tendinopathy, that may be evident on imaging (Gibbon et al. 1999). Partial tears are frequently reported in surgical series in individuals with long standing Achilles tendinosis (Astrom 1997). It remains unclear whether normal tendon with tightly bundled Type I collagen fibres can rupture in the transverse plane in small sections of a tendon. Pathology studies to date describe longitudinal separation and unplaiting of tendons rather than frank transverse tearing (Józsa et al. 1990, 1991).

Received: 7 November 2001

Accepted: 22 March 2002

Jill L Cook, PhD, PG Dip Manip Phys, B App Sci (Phys), Musculoskeletal Research Centre, La Trobe University, Victoria 3086, Australia; **Karim M. Khan, PhD, MD**, Department of Family Practice (Allan McGavin Sports Medicine Centre) and School of Human Kinetics, University of British Columbia, Canada; **Craig Purdam, M Sports Phys, Dip Phys**, Head of Physiotherapy and Massage, Australian Institute of Sport, Canberra, Australia.

Correspondence to: J. Cook. Tel.: +61 3 9479 5789; Fax: +61 3 9479 5768; E-mail: j.cook@latrobe.edu.au

Anatomy

The Achilles tendon is the single tendon of the soleus and gastrocnemius muscles, inserting into the calcaneum. It has a highly structured peritendinous tissue with no synovial membrane. The blood supply to the tendon enters on the deep (anterior) surface, and

appears to be similar in volume throughout its length (Ahmed et al. 1998). The presence of a hypovascular region that has been suggested to be a predisposing factor for midtendon tendinopathy was not supported in a study by Astrom using laser Doppler flowmetry (Astrom & Westlin 1994).

The Achilles tendon lies close to several structures important in differential diagnosis of lower leg pain. These structures include the sural nerve, the posterior ankle structures, the medial tendons of the foot and toes and the bursae near the calcaneum. Pathology in these surrounding structures can mimic Achilles tendon pain, either in the midtendon or insertional area.

Microanatomy

Normal tendon structure comprises sparse spindle-shaped tendon cells interspersed with a highly organized extracellular matrix. The tendon cells are responsible for the synthesis of all components of the extracellular matrix.

The matrix has tight bundles of long strands of Type I collagen, which give the tendon its inherent strength. Between the collagen, and a vital part of tendon structure, is the ground substance, made up of mainly small proteoglycans and glycosaminoglycan chains. In normal tendon, there is minimal ground substance and it is not evident under light microscopic examination. Connective tissue (endotendon) lies parallel with the collagen bundles, enclosing and separating tendon fascicles (Fig. 1). Vascular and neural structures run between the collagen fascicles in conjunction with this connective tissue (O'Brien 1992).

The peritendon is a fine loose connective tissue sheath comprising the epitendon (over the tendon) and the paratenon (outer layer). Connective tissue of the peritendon and the tendon are continuous with each other. The Achilles peritendon does not have a synovial layer found in hand and wrist tendons but is differentiated posteriorly into a number of fine gliding membranes lubricated by mucopolysaccharides (Lang 1960).

Histopathology

Tendons respond poorly to overuse, and healing is slow, incomplete and lacks extracellular organization. This has been termed tendon degeneration (Leadbetter 1992), but may be more accurately defined as a failed healing response (Clancy 1989). This process leaves the pathological tendon substantially defective, which decreases tendon strength and leaves it less able to tolerate load and thus, vulnerable to further injury.

Acute tendon injuries heal with a standard triphasic response, inflammation, proliferation and maturation, and return slowly to a structure that resembles normal tendon organization (Frank et al. 1999). It is unclear why overuse tendinopathy does not respond with this triphasic response. The process of tendon disruption that leads to microinjury is unknown, and it may fail to stimulate an adequate inflammatory response, required to begin the reparative cycle. Surgery for tendons that fail conservative treatment injures the tendon and creates a vascular disruption, which stimulates the triphasic repair process.

Microscopically, pathological tendon is in direct contrast to normal tendon, and the hallmarks of overuse tendinopathy are distinct. Primarily, large increases in the amount of ground substance are apparent, and this ground substance has a greater proportion of large proteoglycans than found in normal tendon (Benazzo et al. 1996).

Increases in ground substance are associated with disruption of the collagen bundles and their hierarchical arrangement (Astrom & Rausing 1995), and a decrease in amount of Type I collagen. Type III collagen is the collagen produced by the cells in response to injury, however, it is thinner and less able to bundle than Type I collagen.

There is an increase in the number of tendon cells, and immigration of fibroblasts from the peritendon and perhaps other areas of tendon may be the source of these cells. The cells become active—rounded in appearance and have increased organelles responsible




Fig. 1—Light microscopic section of normal Achilles tendon (with permission Prof. N. Maffulli).

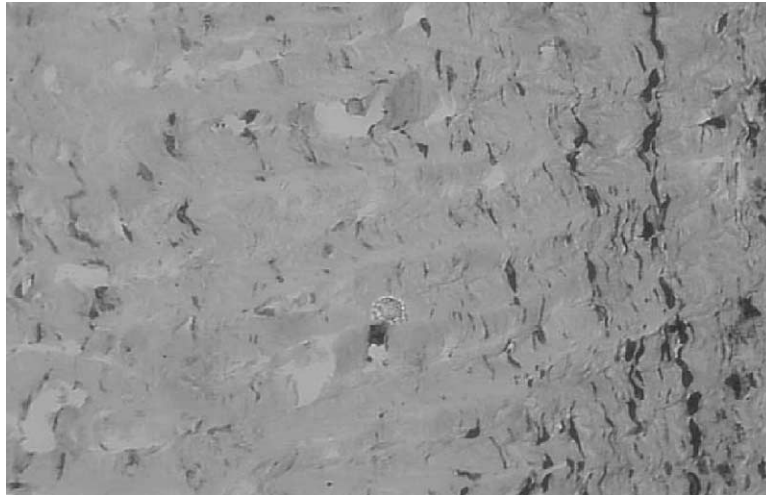


Fig. 2—Achilles tendinopathy. Note the increase in cell population (with permission Prof. N. Maffulli).

for protein synthesis (collagen and ground substance) (Fig. 2).

Some areas of tendinopathy become acellular (cystic tendinopathy) (Khan et al. 1996) or have decreased cell numbers and function, (hypoxic degeneration) (Józsa et al. 1990). The cause of different cellular reactions and consequently different types of pathology is unknown. Several types of pathology can be found in the same tendon.

Vascularity is increased in tendinopathy (Ohberg et al. 2001), some new vessels are reported to be thick walled, tortuous and have small lumen. The function of these vessels is questionable as the tendon surrounding these vessels does not appear to have an advanced repair process (Kraushaar & Nirschl 1999).

The large amounts of ground substance, inferior collagen and vascularity are randomly arranged and lack organization, making the tendon less load tolerant. Exercise may offer a stimulant to improving the organization of these components (Wren et al. 2000); however further research is required.

Peritendinous injury is a rarer presentation in the spectrum of Achilles tendon injury. Repeated cyclic movement of the tendon, such as cycling may aggravate the peritendon. Peritendinopathy can exist by itself or in conjunction with tendinopathy (Khan et al. 1999). In contrast to tendon injury, peritendinitis is distinctly inflammatory in nature (Kvist et al. 1992).

AETIOLOGY OF ACHILLES TENDON INJURY

The Achilles tendon is reported to be affected by the biomechanics of the foot, the footwear of the person and the relative range of motion in the foot and ankle joint. Clinically, it is assumed that the behaviour of the foot in walking and running affects the homo-

geneity of the Achilles tendon load, but this is not supported in some research (Astrom 1997).

Research suggests that decreased ankle dorsiflexion is a risk factor for Achilles tendon pain (Kaufman et al. 1999). This appears logical clinically, as the tendon must absorb load over a shorter range of movement and in less time.

Change in tendon load is also reported to be associated with Achilles tendon symptoms (Clement et al. 1984), and clinically this is reported regularly. As yet, it has not been shown what amount of load or what change in load will increase tendon pathology or symptoms.

DIAGNOSIS

Achilles tendon injury is one of the simpler clinical diagnoses to make. The history is classic for both acute and overuse tendon injury and inflammation of the peritendinous tissues. In overuse tendinopathy, the person can often recall a change in activity levels or training techniques, with an insidious and gradual increase in symptoms. Originally the pain may not be disabling, but with continued activity, it can begin to affect the person's ability to train effectively. Rest will often relieve symptoms, but return to activity reactivates the pain, generally within a few training sessions.

The Achilles tendon is the only major tendon that must tolerate almost full range of movement including stretch immediately on rising in the morning. Hence, morning pain is a hallmark of Achilles tendinopathy; the degree and time of stiffness are considered good indicators of tendon health and recovery from injury. Rest from training can also decrease morning stiffness, but often it will return with an increase in activity.

VISA-A Achilles tendon questionnaire

IN THIS QUESTIONNAIRE, THE TERM PAIN REFERS SPECIFICALLY TO PAIN IN THE ACHILLES TENDON REGION

1. For how many minutes do you have stiffness in the Achilles region on first getting up?

0 mins

1	2	3	4	5	6	7	8	9	10
---	---	---	---	---	---	---	---	---	----

 100 mins POINTS

2. Once you are warmed up for the day, do you have pain when stretching the Achilles tendon fully over the edge of a step? (keeping knee straight)

Strong severe pain

1	2	3	4	5	6	7	8	9	10
---	---	---	---	---	---	---	---	---	----

 No pain POINTS

3. After walking on flat ground for 30 minutes, do you have pain within the next 2 hours? (If unable to walk on flat ground for 30 minutes because of pain, score 0 for this question).

Strong severe pain

1	2	3	4	5	6	7	8	9	10
---	---	---	---	---	---	---	---	---	----

 No pain POINTS

4. Do you have pain walking downstairs with a normal gait cycle?

Strong severe pain

1	2	3	4	5	6	7	8	9	10
---	---	---	---	---	---	---	---	---	----

 No pain POINTS

5. Do you have pain during or immediately after doing 10 (single leg) heel raises from a flat surface?

Strong severe pain

1	2	3	4	5	6	7	8	9	10
---	---	---	---	---	---	---	---	---	----

 No pain POINTS

6. How many single leg hops can you do without pain?

None

1	2	3	4	5	6	7	8	9	10
---	---	---	---	---	---	---	---	---	----

 10 hops POINTS

7. Are you currently undertaking sport or other physical activity?

- 0 Not at all POINTS
 4 Modified training ± modified competition
 7 Full training ± competition but not at same level as when symptoms began
 10 Competing at the same or higher level as when symptoms began

8. Please complete EITHER A, B or C in this question.

- If you have **no pain while undertaking sport** please complete **Q8a only**.
- If you have **pain while undertaking sport but it does not stop you from completing the activity**, please complete **Q8b only**.
- If you have **pain which stops you from completing sporting activities**, please complete **Q8c only**.

A. If you have **no pain** while undertaking sport, for how long can you train/practise?

NIL	1-10 mins	11-20 mins	21-30mins	>30 mins	POINTS
<input type="checkbox"/>	<input type="checkbox"/>	<input type="checkbox"/>	<input type="checkbox"/>	<input type="checkbox"/>	<input type="checkbox"/>
0	7	14	21	30	

OR

B. If you have some pain while undertaking sport, but it does not stop you from completing your training/practice for how long can you train/practise?

NIL	1-10 mins	11-20 mins	21-30mins	>30 mins	POINTS
<input type="checkbox"/>	<input type="checkbox"/>	<input type="checkbox"/>	<input type="checkbox"/>	<input type="checkbox"/>	<input type="checkbox"/>
0	4	10	14	20	

OR

C. If you have **pain that stops you** from completing your training/practice, for how long can you train/practise?

NIL	1-10 mins	11-20 mins	21-30mins	>30 mins	POINTS
<input type="checkbox"/>	<input type="checkbox"/>	<input type="checkbox"/>	<input type="checkbox"/>	<input type="checkbox"/>	<input type="checkbox"/>
0	2	5	7	10	

TOTAL SCORE (/100) %

Fig. 3—VISA-A Achilles tendon questionnaire.

Symptoms of tendinopathy are localized to the tendon and immediate surrounding area. As tendon pain is usually localized to the tendon and does not appear to refer to other regions, symptoms that are vague or encompass a larger area are suggestive of another source of pain, or perhaps tendon pain in conjunction with other pathology.

The VISA-A (Fig. 3) scale is a subjective rating scale that quantifies the symptoms and dysfunction in the Achilles tendon (Robinson et al. 2001). This assessment tool is very useful to rate Achilles tendons and to assess progress of recovery during rehabilitation. Other clinical tests and questionnaires have also been used to evaluate treatment outcomes (Silbernagel et al. 2001).

Acute tendon rupture will be reported as a sensation of a blow on the tendon and a loss of function, but may not be associated with considerable pain. Peritendinitis results in crepitus, swelling and exquisite tenderness.

On examination, the tendon can appear completely normal, but more often will have subtle changes in outline, becoming thicker in both the anteroposterior and mediolateral plane. The increase in anteroposterior diameter may be difficult to detect clinically, but is classically in the midtendon, and can be very focal or broader in area.

Swelling and pain at the attachment is less common and must be assessed fully, differential diagnosis includes pain associated with bony prominences (Haglund's deformity, pump bumps, calcaneal spurs) and bursae (Haglund's, retrocalcaneal). Longitudinal and transverse tears at the bone-tendon junction

have been demonstrated at this site (Rufai et al. 1995). Athletically, pain at the insertion may be seen in individuals with large range of dorsiflexion where the calcaneum can impinge on the anterior aspect of the tendon. Insertional pain may have a systemic cause and this aetiology must be fully explored.

A complete examination of the athlete should include the biomechanics of the foot, ankle and leg during walking and running, and include slow motion analysis. Barefoot and examination in athletic shoes and with and without orthotics (if used) should be made. Range of ankle dorsiflexion should be quantified in standing and the difference between the neutral foot and the pronated foot used should be noted. The number and quality of single leg heel raises and hops, noting pain and endurance, should be recorded.

Finally, gentle palpation of the tendon and surrounding structures and the calf muscle should be made. Palpation tenderness may guide the examiner to the area of tendon that has subtle swelling or specific nodules. Palpation should include assessment of tendon compliance, muscle tightness, and fluctuance of swelling (Williams 1986)

Palpation tenderness is not a clinically useful diagnostic sign as small amounts of pressure provoke pain in tendons. Palpation tenderness has been shown not to correlate with imaging changes or symptoms in the patellar tendon (Cook et al. 2001).

Peritendon involvement can be difficult to assess clinically, although full blown peritendinitis is easily recognized, with exuberant swelling, crepitus and the classic sign of the swelling not moving with tendon

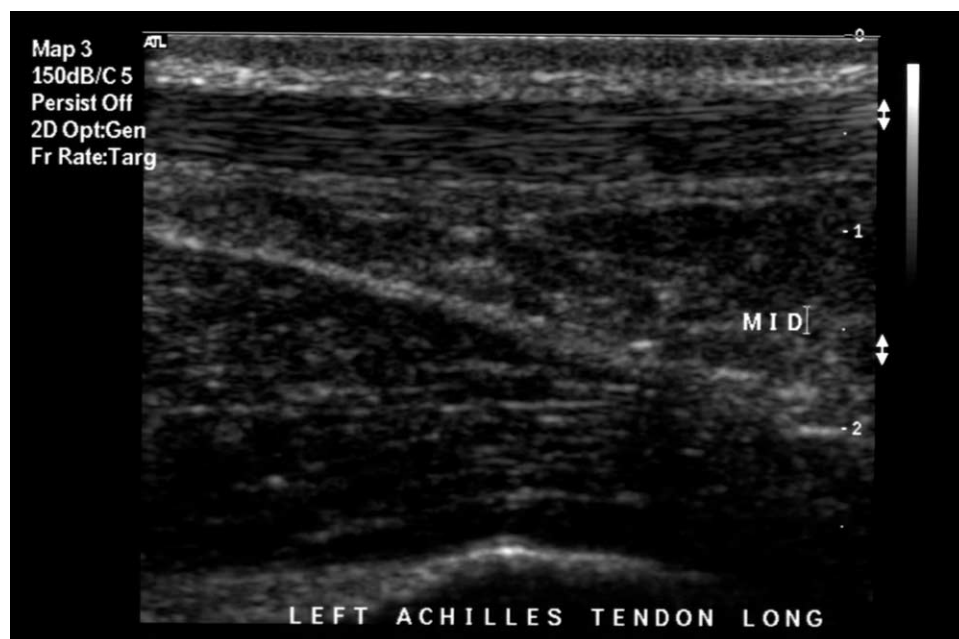

Fig. 4—A normal Achilles tendon.

movement. More commonly, the line between tendon only and combined pathology can only be assessed effectively by imaging.

A complete rupture can be determined from the calf squeeze test (Maffulli 1998), squeezing the calf in prone does not elicit any movement of the foot. Partial ruptures are impossible to diagnose clinically and present an imaging dilemma as well, as long-standing tendinopathy may appear on imaging with discontinuity of collagen fascicles.

IMAGING

Superficial tendons are very amenable to imaging with ultrasound and the Achilles is no exception. Ultrasound images provide a clear indication of tendon width, changes of water content within the tendon and peritendon and collagen integrity. A normal tendon appears consistent in width and anteroposterior diameter with continuous fascicles and thin hyperechogenic peritendinous structures (Fig. 4).

In contrast, an abnormal tendon will reveal at the very least an increase in tendon diameter, but often shows areas of increased water (hypoechoic), collagen discontinuity and tendon sheath swelling. Small areas of calcification may also be visible. Ultrasound can also detect bursal swelling, an important differential diagnosis in Achilles tendinopathy (Gibbon et al. 2000) (Fig. 5).

Ultrasound should be the imaging modality of first choice in Achilles tendon, as it is inexpensive and available, and clearly defines the pathology (Davies et al. 1991). If the diagnosis is unclear or the

symptoms are atypical, magnetic resonance imaging (MRI) may be worthwhile. MRI is also very sensitive to pathology, which appears as increased signal within the Achilles tendon (Haims et al. 2000) (Fig. 6). MRI is often most effective when several structures in the region need imaging.

Differential diagnosis

A multitude of structures are implicated in the differential diagnosis in the Achilles region but a good clinical examination should allow accurate diagnosis. Posterior ankle impingement, medial tendon tendinopathy, and bursitis are relatively easy to diagnose. Sural nerve symptoms and referred pain from a spinal region are more difficult to diagnose.

Pain that is non-specific in nature and not clearly related to tendon loading are clues to these more complex diagnoses that should include systemic inflammatory diseases. Sciatic nerve irritation may be associated with Achilles tendon rupture through several possible mechanisms (Maffulli et al. 1998).

TREATMENT OF TENDINOPATHY

The object of any treatment in any condition is to decrease pain and improve tissue function. In tendinopathy the source of the pain is undefined (Khan & Cook 2000), and the effect of conservative or physiotherapeutic interventions on tendinopathic tissue is poorly understood. We are therefore forced to acknowledge that whilst some interventions have been demonstrated to improve musculotendinous

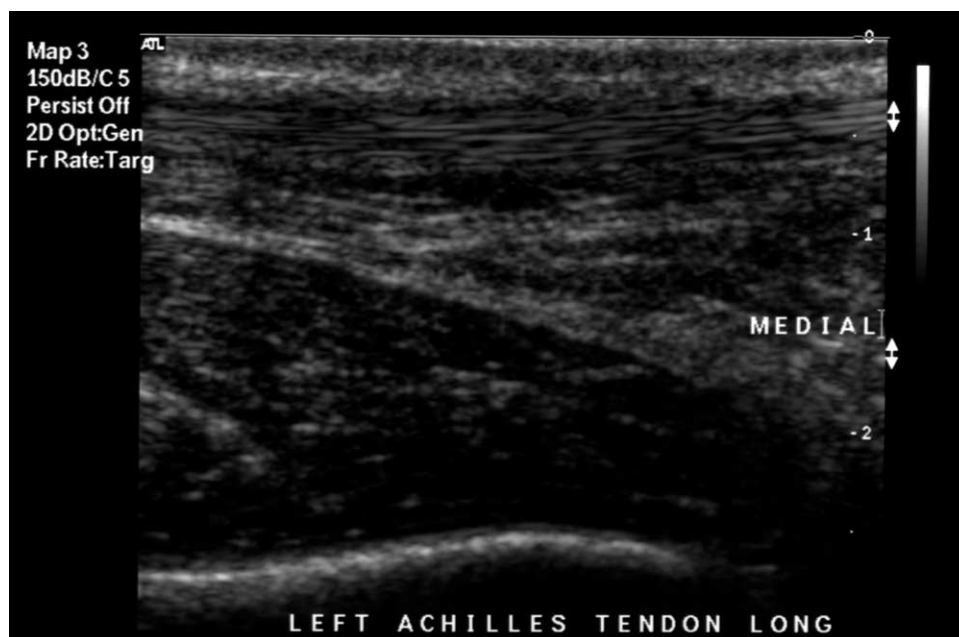

Fig. 5—An abnormal Achilles tendon on US. Note the thicker tendon, and areas of hypoechoic.

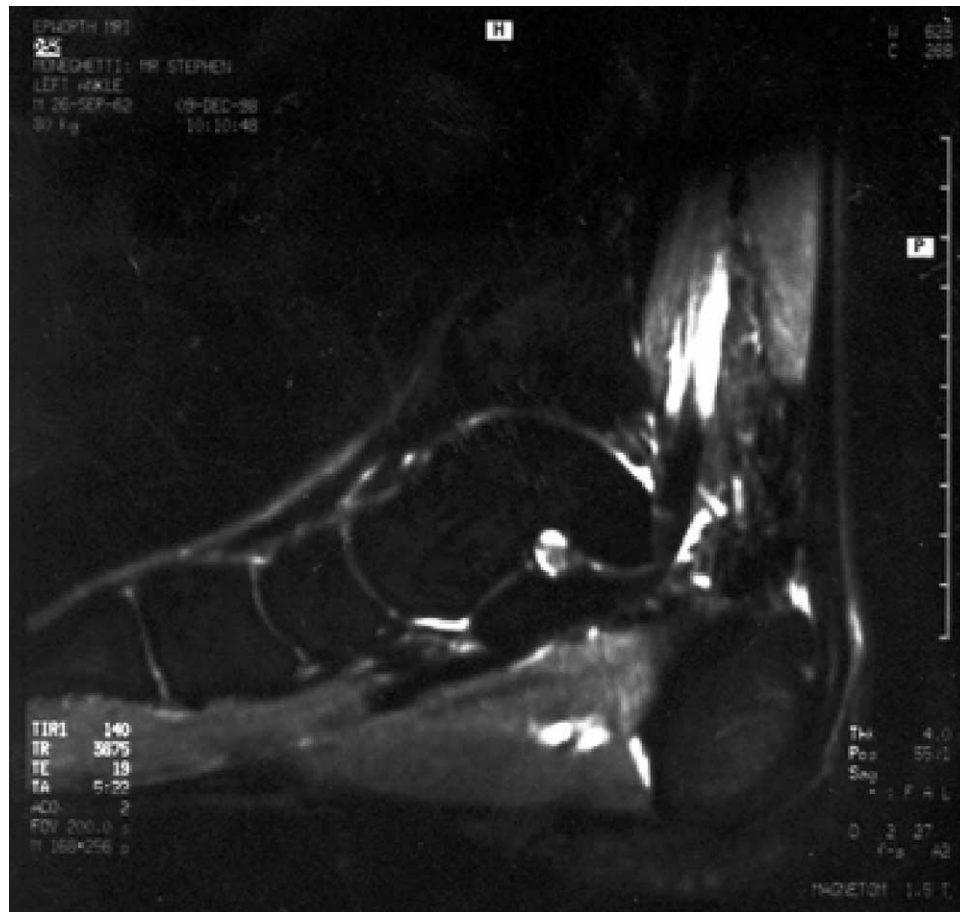


Fig. 6—An MRI of an Achilles tendon. Note the slight increase in signal of the attachment.

function, we are currently unable to define how, where and why this occurs.

Musculotendinous strengthening appears to be essential in tendon rehabilitation. It appears that the nature of this strength program should be strongly biased towards eccentric muscle contraction (Mafi et al. 2001). It is unclear if eccentric muscle contraction equips the muscle for better sporting function, or if it directly affects tendon pathology, as the stimulus for repair in pathologic tendon tissue remain elusive. It should be considered however, that exercise appears to be the only stimulus described to date that positively influences collagen alignment (Kannus et al. 1997).

Rest as a treatment for tendinopathy stems from the previous inflammatory paradigm of tendinitis, and will be effective in reducing pain, but offers no improvement in musculotendinous function. In fact rest appears to affect tendon tissue negatively, reducing collagen amount and strength (Kannus et al. 1997).

Conservative treatment

As exercise-based program is essential in tendon rehabilitation, appropriate and progressive exercises

must be prescribed if rehabilitation is to succeed. Inadequate amounts of load, speed and endurance may result in incomplete rehabilitation and insufficient musculotendinous strength to return to sport.

Eccentric exercise was first reported by Curwin and Stanish (1984) as a useful intervention for tendinopathy. They reported that eccentric exercise resolved symptoms in a 6-week period. The program was progressed by increasing speed and load, subject to symptoms. A recent study by Alfredson et al. (1998) reported excellent results with heavy load eccentric exercise. This program varied considerably from that proposed by Curwin and Stanish in that speed was not used as a progression of the exercise, pain was not a contraindication to continuing exercises and the eccentric component of the exercise was completed single leg.

Currently, this regime remains the gold standard for Achilles tendon rehabilitation and appears effective in most athletes. Recent studies have further supported the use of eccentric exercise (Silbernagel et al. 2001). In competitive athletes, the exercise programme may need to be progressed to a level beyond that prescribed by Alfredson, in order to address specific muscle hypertrophy, speed, strength and endurance requirements of specific sports.

Manipulation of training load in athletes may be an essential management strategy in conjunction with an eccentric exercise program. Reduction of volume, intensity, speed and repetitions may all spare the tendon sufficiently to reduce symptoms and allow progression of rehabilitation. Occasionally, complete rest or cessation of training may be required to settle severe symptoms.

Electrophysical modalities are useful to modulate pain and appear to be more effective in well vascularized tissue. As tendon pain commonly produces symptoms under load, and is poorly vascularized, these modalities offer little in the treatment of Achilles tendinopathy.

The effectiveness of manual therapy for the Achilles tendon remains unclear. In vitro studies suggest that physical manipulation of tendon cells may affect the cellular output (Almekinders et al. 1993); however, there is little evidence that this occurs in vivo (Wilson et al. 2000). Hunter (2000) proposes tendon mobilization and restoration of accessory movement of the tendon and surrounding structures. Massage for peritendinitis will increase the inflammatory reaction and is not recommended.

Ensuring flexibility of the musculotendinous unit and the ankle joint is an important component of rehabilitation. In some athletes effective ankle joint interventions may be difficult, as many jumping sports are associated with recurrent ankle injury, talocrural degeneration and anterior impingement. Improving ankle dorsiflexion in any athlete is difficult, and only small gains may be possible. Flexibility of both components of the calf is important, and stretches should address this. Regular massage during rehabilitation is beneficial, to assist muscle recovery during the strengthening process. Specific soft tissue releases may also be utilized.

Correction of biomechanical imperfections is clinically important even if it is unclear if this directly affects tendon recovery. Alteration in the amount and/or speed of foot pronation is considered to be the most useful intervention. Control of foot mechanics in athletes is best achieved with tailored, rigid orthotic prescription. Heel raises to decrease tendon load are also often prescribed, the effectiveness of this has not been demonstrated.

Long-term followup (mean 8 years) of Achilles tendon symptoms has shown that one-third required surgery, but of those that responded to a variety of conservative management, most recovered fully (Paavola et al. 2000).

Difficult tendons

When pain prevents an athlete training and playing, full attention and compliance to rehabilitation is possible. However, when an athlete can continue to train or compete with pain, rehabilitation becomes

more complex. Introducing exercises to strengthen the musculotendinous unit appears unnecessary, as maximal muscle function should be gained during training. Despite athletic competence and ability to remain competitive, athletes often favour their symptomatic leg and place excessive load onto the unaffected leg, resulting in loss of strength and function despite ongoing sports participation. Hence, specific exercise programmes tailored to these deficits may still have a place in the competing athlete.

Poor compliance to load management and exercise by the athlete decreases the effectiveness of rehabilitation. These athletes may partially recover and return to abusive loads prematurely, only to have a return of pain. Several relapses will often force longer term compliance on athletes, however some seek an 'easy' surgical treatment without understanding the implications of, and recovery time from, this intervention.

Some tendons fail to recover despite adequate practitioner and athlete involvement. Increased intensity of exercise (speed, change of direction), and return to training and competition are common points of failure. Further management may allow return to sport, but long-term training modification (training quality or quantity) may be necessary.

Peritendinous treatment

Acute peritendinopathy has been difficult to manage, with anti-inflammatory treatment offering somewhat mixed outcomes. More recently, and based on early work by Rais (1961), the use of heparin and its derivatives either locally within the peritendon or systemically offer excellent clinical recovery in a few days. Chronic peritendinopathy will not respond to this regime.

Surgical treatment

Failure to respond to a complete conservative rehabilitation programme necessitates surgical intervention if the athlete is to have an opportunity to return to sport at their desired level. Tendon surgery however, does not guarantee success, and rehabilitation times are often prolonged and outcomes may be less than satisfactory (Maffulli et al. 1999a). A recent review of Achilles tendon surgery by Tallon et al. (2001) revealed experimental design flaws in some studies reporting outcomes after Achilles tendon surgery. Further quality research in this area is required.

Tendon rupture

The Achilles tendon is the most common tendon to rupture spontaneously (Kannus & Józsa 1991). The highest incidence of tendon rupture occurs in men

between 30 and 39 years, whereas women appear to be protected until the post-menopausal years (Maffulli et al. 1999b). Tendons that rupture are nearly always pathological prior to rupture, although only one-third were reported to be symptomatic prior to rupture (Kannus & Józsa 1991).

Surgical repair after rupture is encouraged in those seeking to continue sports participation, as the rerupture rate in those treated conservatively has been shown to be significantly higher than those treated surgically (Moller et al. 2001). If the tendon remains intact, the long-term outcomes in those managed conservatively has been reported to be similar to those treated operatively (Bressel 2001); however, long-term deficits in endurance capacity, range of movement and calf bulk have also been reported (Horstmann et al. 2000).

CONCLUSION

Achilles tendon injury is a relatively simple diagnostic condition in both acute and overuse injury. Recent techniques of rehabilitation produce a very good outcome in the majority of cases, however the evidence that underpins the mechanism of effective treatment is lacking. Failure to respond to conservative treatment requires surgical treatment, although a satisfactory outcome following this procedure is not guaranteed. Further research is required to improve the management of this condition.

References

- Ahmed I, Lagoloulos M, McConnell P, Soames R, Sefton G 1998 Blood supply of the Achilles tendon. *Journal of Orthopaedic Research* 16(5): 591–596
- Alfredson H, Pietila T, Jonsson P, Lorentzon R 1998 Heavy-load eccentric calf muscle training for the treatment of chronic Achilles tendinosis. *American Journal of Sports Medicine* 26(3): 360–366
- Almekinders LC, Banes AJ, Ballenger CA 1993 Effects of repetitive motion on human fibroblasts. *Medicine and Science in Sport and Exercise* 25(5): 603–607
- Astrom M, Westlin N 1994 Blood flow in the normal Achilles tendon assessed by laser Doppler flowmetry. *Journal of Orthopaedic Research* 12(2): 246–252
- Astrom M, Rausing A 1995 Chronic Achilles tendinopathy. A survey of surgical and histopathologic findings. *Clinical Orthopaedics* 316: 151–164
- Astrom M 1997 On the nature and etiology of chronic Achilles Tendinopathy, Lund University, Sweden
- Benazzo F, Stennardo G, Valli M 1996 Achilles and patellar tendinopathies in athletes: pathogenesis and surgical treatment. *Bull Hospital Joint Disease* 54: 236–240
- Bressel E 2001 Biomechanical behavior of the plantar flexor muscle-tendon unit after an Achilles tendon rupture. *American Journal of Sports Medicine* 29(3): 321–326
- Cameron DM, Bohannon RW, Owen SV 1994 Influence of hip position on measurements of the straight leg raise test. *Journal of Orthopaedic and Sports Physical Therapy* 19(3): 168–172
- Clancy W 1989 Failed healing responses. In: Leadbetter W, Buckwater J, Gordon S (eds) *Sports-Induced Inflammation: Clinical and Basic Science Concepts*. American Orthopedic Society for Sports Medicine, Park Ridge, IL
- Clement DB, Taunton JE, Smart GW 1984 Achilles tendinitis and peritendinitis. Etiology and treatment. *The American Journal of Sports Medicine* 12: 179–184
- Cook J, Khan K, Kiss S, Purdam C, Griffiths L 2001 Reproducibility and clinical utility of tendon palpation to detect patellar tendinopathy in young basketball players. *British Journal of Sports Medicine* 35: 65–69
- Curwin S, Stanish WD 1984 *Tendinitis: its etiology and Treatment*. Collamore Press, Lexington
- Davies SG, Baudovin CJ, King JB, Perry JD 1991 Ultrasound, computed tomography and magnetic resonance imaging in patellar tendinitis. *Clinics in Radiology* 43: 52–56
- Frank C, Shrive N, Hiraoka H, Nakamura N, Kaneda Y, Hart D 1999 Optimisation of the biology of soft tissue repair. *Journal of Science and Medicine in Sport* 2(3): 190–210
- Gibbon W, Cooper J, Radcliffe G 2000 Distribution of sonographically detected tendon abnormalities in patients with a clinical diagnosis of chronic Achilles tendinosis. *Journal of Clinical Ultrasound* 28: 61–66
- Gibbon WW, Cooper JR, Radcliffe JS 1999 Sonographic incidence of tendon microtears in athletes with chronic Achilles tendinosis. *British Journal of Sports Medicine* 33: 129–130
- Haims A, Schweitzer M, Patel R, Hecht P, Wapner K 2000 MR imaging of the Achilles tendon: overlap of findings in symptomatic and asymptomatic individuals. *Skeletal Radiology* 29: 640–645
- Horstmann T, Lukas C, Mayer F et al. 2000 Isokinetic strength and strength endurance of the lower limb musculature ten years after achilles tendon repair. *Isokinetics and Exercise Science* 8: 141–145
- Hunter G 2000 The conservative management of Achilles tendinopathy. *Physical Therapy in Sport* 1: 6–14
- Józsa L, Kannus P, Balint JB, Reffy A 1991 Three-dimensional ultrastructure of human tendons. *Acta Anatomica* 142: 306–312
- Józsa L, Reffy A, Kannus P, Demel S, Elek E 1990 Pathological alterations in human tendons. *Archives of Orthopaedic and Trauma Surgery* 110: 15–21
- Kannus P, Józsa L 1991 Histopathological changes preceding spontaneous rupture of a tendon. *Journal of Bone and Joint Surgery* 73A: 1507–1525
- Kannus P, Józsa L, Natri A, Jarvinen M 1997 Effects of training, immobilization and remobilization on tendons. *Scandinavian Journal of Medicine and Science in Sports* 7: 67–71
- Kaufman K, Brodine S, Shaffer R, Johnson C, Cullison T 1999 The effect of foot structure and range of motion on musculoskeletal overuse injuries. *American Journal of Sports Medicine* 27(5): 585–593
- Khan K, Cook J 2000 Overuse tendon injuries: where does the pain come from? *Sports Medicine and Arthroscopy Reviews* 8: 17–31
- Khan KM, Bonar F, Desmond PM et al. 1996 Patellar tendinosis (jumper's knee): findings at histopathologic examination, US and MR imaging. *Radiology* 200: 821–827
- Khan KM, Bonar SF, Cook JL, Harcourt PR, Astrom M 1999 Histopathology of common overuse tendon conditions: update and implications for clinical management. *Sports Medicine* 6: 393–408
- Kraushaar B, Nirschl R 1999 Tendinosis of the elbow (tennis elbow). Clinical features and findings of histological, immunohistochemical, and electron microscopy studies. *Journal of Bone and Joint Surgery America* 81(2): 259–278
- Kvist M, Józsa L, Jarvinen M 1992 Vascular changes in the ruptured Achilles tendon and its paratenon. *International Orthopaedics* 16: 377–382
- Lang J 1960 Gliding tissue of muscles, fascias and blood vessels *Zeitschrift fuer Anatomie und Entwicklungsgeschichte* 122: 197–231
- Leadbetter W 1992 Cell matrix response in tendon injury. *Clinics in Sports Medicine* 11(3): 533–578
- Maffulli N 1998 The clinical diagnosis of subcutaneous tear of the Achilles tendon. A prospective study in 174 patients. *American Journal of Sports Medicine* 26(2): 266–270
- Maffulli N, Irwin A, Kenward M, Smith F, Porter R 1998 Achilles tendon rupture and sciatica: a possible correlation. *British Journal of Sports Medicine* 32: 174–177

- Maffulli N, Binfield P, Moore D, King J 1999a Surgical decompression of chronic central core lesions of the Achilles tendon. *American Journal of Sports Medicine* 27(6): 747–752
- Maffulli N, Waterston W, Squair J, Reaper J, Douglas H 1999b Changing incidence of Achilles tendon rupture in Scotland: a 15 year study. *Clinical Journal of Sports Medicine* 9(3): 157–160
- Maffulli N, Barrass V, Ewen S 2000 Light microscopic histology of Achilles tendon ruptures. *American Journal of Sports Medicine* 28(6): 857–863
- Mafi N, Lorentzon R, Alfredson H 2001 Superior short-term results with eccentric calf muscle training compared to concentric training in a randomized prospective multicenter study on patients with chronic Achilles tendinosis. *Knee Surgery Sports Traumatology Arthroscopy* 9: 42–47
- Moller M, Movin T, Granhed H, Lind K, Faxen E, Karlsson J 2001 Acute rupture of the tendon Achilles. *Journal of Bone and Joint Surgery (Br)* 83-B: 843–848
- O'Brien M 1992 Functional anatomy and physiology of tendons. *Clinics in Sports Medicine* 11(3): 505–520
- Ohberg L, Lorentzon R, Alfredson H 2001 Neovascularisation in Achilles tendons with painful tendinosis but not in normal tendons: an ultrasonographic investigation. *Knee Surgery Sports Traumatology Arthroscopy* 9: 233–238
- Paavola M, Kannus P, Paakkala T, Pasanen M, Jarvinen M 2000 Long-term prognosis of patients with Achilles tendinopathy. *American Journal of Sports Medicine* 28(5): 634–642
- Rais O 1961 Heparin Treatment of Peritendinitis (Peritendinitis) Crepitans Acuta. *Acta Chirurgica Scandinavica Supplementum* 268
- Robinson JM, Cook JL, Purdam C et al. 2001 The VISA-A questionnaire: a valid and reliable index of the clinical severity of Achilles tendinopathy. *British Journal of Sports Medicine* 35: 335–341
- Rufai A, Ralphs JR, Benjamin M 1995 Structure and histopathology of the insertional region of the human Achilles tendon. *Journal of Orthopaedic Research* 13: 585–593
- Silbernagel K, Thomee R, Thomee P, Karlsson J 2001 Eccentric overload training for patients with chronic Achilles tendon pain—a randomised testing of the evaluation methods. *Scandinavian Journal of Medicine and Science in Sports* 11(4): 197–206
- Tallon C, Coleman B, Khan K, Maffulli N 2001 Outcome of surgery for chronic Achilles tendinopathy. *American Journal of Sports Medicine* 29(3): 315–320
- Tuite DJ, Renstrom PAFH, O'Brien M 1997 The aging tendon. *Scandinavian Journal of Medicine and Science in Sports* 7: 72–77
- Williams JG 1986 Achilles tendon lesions in sport. *Sports Medicine* 3: 114–135
- Wilson JK, Sevier TL, Helfst R, Honong E, Thomann A 2000 Comparison of rehabilitation methods in the treatment of patellar tendinitis. *Journal of Sports Rehabilitation* 9: 304–314
- Wren T, Beaupre G, Carter D 2000 Tendon and Ligament adaption to exercise, immobilisation and remobilisation. *Journal of Rehabilitation Research and Development* 37(2): 217–224